



## Role of MRI in evaluating traumatic and non-traumatic knee pain

Mohammed Ali Abdulhafed<sup>1</sup>, Qais Abdulqader Abdulrazzaq<sup>2</sup>, Mustafa Saad Yassin<sup>3</sup>

<sup>1</sup> Radiologist, Abo gharaeb Hospital, Baghdad, Iraq

<sup>2</sup> Radiologist, Baqubah Teaching Hospital, Diyala, Iraq

<sup>3</sup> Radiologist, Baqubah Teaching Hospital, Diyala, Iraq

### Abstract

**Background:** Knee pain is a common complaint that affects people of all ages. Knee pain may be the result of an injury which can affect any of the ligaments, tendons or fluid-filled sacs bursa that surround knee joint as well as the bones, cartilage and ligaments that form the joint itself. MRI Provides excellent soft tissue contrast and is capable of evaluating soft tissue and bony structures in multiple imaging planes which provides significant advantages over other imaging techniques, MRI have also been demonstrated as a cost effective Technique by reducing unnecessary surgical and Arthroscopic interventions. It is regarded as the top imaging and diagnostic tool for the knee joint as a result of its ability to evaluate a wide range of anatomy and pathology varying from ligamentous injuries to articular cartilage lesions

**Aim of the Study:** The aim of the study is to evaluate the role of MRI in evaluation of patients with Traumatic and Non-Traumatic Knee Pain.

**Materials and Method:** 30 patients were included in the study, from them 10 patients were excluded according to the Exclusion criteria and 20 patients were included according to the inclusion criteria (6 females (30%) & 14 male (70%). The age of the patients is 21-63 years. The study was done in Baqubah Teaching hospital /Diyala /Iraq from November 2020 till October 2021.

**Result:** This study shows that Among the 40 patients who had knees pain, 30 of them, their pain were due to traumatic causes (75%), and the other 10 due to non-traumatic causes (25%). Meniscus injuries founded in 28 patients, (70.00%) of total, 20 patients of them(71.43%) due to trauma and other 8 patients(28.57 %) without history of trauma. Anterior cruciate ligament injuries appeared in 18 cases (45.00% of total), 8 of them (44.44%) had sprained Anterior cruciate ligament, 6 (33.33%) had partial Anterior cruciate ligament tear, and 4 (22.22%) had complete tear. Bone Marrow contusion appeared in 12 cases (30.00%). 10 of them (83.33 %) with traumatic history and other 2(16.67 %) without.

Joint effusion detected in 24 patients about (60.00%) of total cases that seen in our study

**Conclusion:** MR imaging is the best imaging modality for diagnosis of different knee lesions and can be considered as replacing of other invasive modalities for diagnosis of different knee lesions and the best plane and pulse sequence for each injury was as following: Sagittal PD FSE sequence for appreciation of the Anterior cruciate ligament, posterior cruciate ligament posterior cruciate ligament and the extensor mechanism tendons, Coronal & Sagittal PD fat suppressed sequence for menisci., PD fat suppressed sequence for menisci, collateral ligaments and articular cartilage and T2W images help in demonstration of joint effusion.

**Keywords:** MRI, traumatic, non-traumatic, knee pain

### Introduction

The knee joint is the largest and most complicated joint in the body. Basically, it consists of two condylar joints between the medial and lateral condyles of the femur and the corresponding condyles of the tibia, and a patellofemoral articulation between patella and the patellar surface of the femur. The fibula is not directly involved in the joint. (Snell, 2007) [24] The tibiofibular articulation though often considered a part of the knee, is in fact not a portion of the true knee joint. The articular surfaces of both the femoral condyles and tibial condyles are covered with hyaline cartilage. (Ryan et al., 2011) [23] Knee pain is a common complaint that affects people of all ages. Knee pain may be the result of an injury which can affect any of the ligaments, tendons or fluid-filled sacs bursae that surround knee joint as well as the bones, cartilage and ligaments that form the joint itself. Or Medical conditions including arthritis also can cause knee pain, More than 100 different types of arthritis exist. The varieties most likely to affect the knee include: Osteoarthritis, Rheumatoid arthritis. Or Mechanical problems that can cause knee pain include: Loose body, Iliotibial band syndrome, dislocated knee cap, Hip or foot pain. Or Other problems such as Chondromalacia patellae patellofemoral pain syndrome (Zeller et al., 2007).

MRI Provides excellent soft tissue contrast and is capable of evaluating soft tissue and bony structures in multiple imaging planes which provides significant advantages over other imaging techniques, MRI have also been demonstrated as a cost effective Technique by reducing unnecessary surgical and Arthroscopic interventions.

interventions. Improved diagnostic accuracy has clearly been demonstrated and MRI is shown to result in change in patient's management in 41% of patients (Arumugam V. et al., 2015) [1].

Magnetic resonance imaging, with its multi-planar capabilities and excellent soft-tissue contrast, has established itself as the leading modality for non\_invasive evaluation of the sports knee injuries (Standaert and Herring, 2009).

### **Traumatic knee pain pathology:**

#### **1. Anterior Cruciate Ligament Injuries:**

The anterior cruciate ligament is the most common disrupted ligament in the knee. Most Anterior cruciate ligament tears occur in younger active individuals, particularly those involved in athletic activities (Dugan, 2005) [4].

#### **2. Meniscal tears**

Individuals with meniscus tear usually complain of pain and swelling as their primary symptoms. The cause of meniscal tears can be divided into two categories: increased force on a normal meniscus, usually resulting in longitudinal or radial tears, and normal forces on a degenerative meniscus, usually producing horizontal tears in the posterior half of the meniscus (Fox, 2007) [6].

#### **3. Medial Collateral Ligament (MCL) injury**

The Medial collateral ligament is the one of the common injured ligaments in the knee, affecting males twice as frequently as females. Medial collateral ligament injuries progress from a simple stretch (grade I) to partial tear (grade II) and complete tear (grade III). Medial collateral ligament injuries result from both contact and noncontact sport. (Miyamoto *et al.*, 2009) [18].

#### **4. Osseous Injuries**

Osseous injuries may be articular, extra-articular, or physeal, and may be related to direct trauma, avulsion forces, or chronic microtrauma. Displaced fractures can be diagnosed easily on radiographs; however, multiple, subtle osseous or osteochondral lesions may not be defined radiographically. (Berquist, 2007) [2].

#### **5. Myotendinous Injuries**

Muscle and tendon injuries about the knee may occur alone or in association with more significant osseous and ligament injuries. Muscle and tendon injuries may be related to direct trauma (muscle contusion) or to indirect trauma with overextension (Kelley & Berquist, 2006) [3].

### **Non Traumatic Knee Pain Pathology**

**Osteoarthritis (OA):** is the most common form of skeletal disorder worldwide and one of the leading causes of pain and disability. The most commonly affected joints are knee (40%). Osteoarthritis is uncommon before 45 years of age. It is estimated that about 60-90% of individuals over the age 65. (Litwic *et al.*, 2013) [3]

MRI has become a key imaging tool for Osteoarthritis research thanks to its ability to visualize pathologies that are not detected on radiographs. MRI enables the following: the joint can be evaluated as a whole organ; multiple tissue changes can be monitored simultaneously over several time points; pathologic changes of pre-radiographic Osteoarthritis can be detected at a much earlier stage of the disease; physiologic changes within joint tissues (e.g., cartilage and menisci) can be assessed before morphologic changes become apparent. (Englund *et al.*, 2011) [5]

### **Patients & Methods**

This study included 50 patients, from them 10 patients were excluded according to the Exclusion criteria, 40 patients included, 28 (70%) male and 12 (30%) female. Their ages range between 21\_63 years (mean age 38.55±13.37 years). All presented by knee pain and were referred to radiology department in Baqubah teaching Hospital /Diyala-Iraq for MRI examination after orthopedic consultation from November 2020 –October 2021. patients had MR imaging of the affected knee joints on high field strength scanners (1.5 T) MRI unite (Achieva, Philips medical system). MRI was performed by knee coil in all cases.

### **Inclusion Criteria**

1. Patients of both sexes, complaining of Knee pain.
2. Any patient with a history of Trauma to Knee joint.
3. Any patient with a history of non-Traumatized knee pain which includes: Osteoarthritis and Rheumatoid Arthritis.

### **Exclusion Criteria**

1. Patients who had surgeries to joint.
2. Patients with Metabolic diseases.
3. Knee Joint Tumors.
4. Early pregnant patients.

5. Any electrically, magnetically or mechanically activated Implants: cardiac pacemakers, Cochlear implants and Hearing Aids.
6. Intracranial aneurysmal clips (unless made of Titanium).

## Results

The result of the study shown in the following table

**Table 1:** Show the distribution of patient according to sex

Gender		
	N	%
Male	28	70.00
Female	12	30.00
Total	40	100.00

**Table 2:** Show the distribution of patient according to age

Age (years)	No.	%
21-30	11	27.5%
31-40	9	22.5%
41-50	8	20.0%
51-60	6	15.0%
61-63	6	15.0%
total	40	100.0%
Range [Mean $\pm$ SD]	38.55 $\pm$ 13.37 years	

**Table 3:** Show the distribution of patient according to pain cause.

Traumatic or non_traumatic		
	N	%
Traumatic	30	75.00
Non Traumatic	10	25.00
Total	40	100.00

**Table 4:** Show the appearance of meniscus injuries.

meniscus injuries		
	N	%
No	12	30.00
Yes	28	70.00
Total	40	100.00

**Table 5:** Show the distribution of meniscus injuries into traumatic and non-traumatic

meniscus injuries		
	N	%
Traumatic	20	71.43
Non Traumatic	8	28.57
Total	28	100.00

**Table 6:** Show the distribution of injuries in Medial & lateral meniscus

	Med. Meniscus		Lat. Meniscus	
	N	%	N	%
Tear	12	50.00	12	75.00
Degeneration	12	50.00	4	25.00
Total	24	100.00	16	100.00

**Table 7:** Show the distribution of anterior cruciate ligament injuries type.

No. of patients have Anterior cruciate ligament injuries		
	N	%
Sprained	8	44.44
Partial tear	6	33.33
Complete tear	4	22.22
Total	18	100.00

**Table 8:** Show the distribution of Anterior cruciate ligament injuries into traumatic and non-traumatic

<b>anterior cruciate ligament injuries</b>		
	<b>N</b>	<b>%</b>
Traumatic	16	88.89
Non Traumatic	2	11.11
Total	18	100.00

**Table 9:** show the appearance percentage of posterior cruciate ligament injuries

<b>posterior cruciate ligament injuries</b>		
	<b>N</b>	<b>%</b>
No	36	90.00
Yes	4	10.00
Total	40	100.00

**Table 10:** Show the Lateral Collateral Ligament injuries distribution.

<b>Lateral Collateral Ligament</b>		
	<b>N</b>	<b>%</b>
No	34	85.00
Yes	6	15.00
Total	40	100.00

**Table 11:** Show the medial Collateral Ligament injuries distribution.

<b>medial Collateral Ligament</b>		
	<b>N</b>	<b>%</b>
No	30	75.00
Yes	10	25.00
Total	40	100.00

**Table 12:** show the percentage of Osteoarthritis changes.

<b>Osteoarthritis change</b>		
	<b>N</b>	<b>%</b>
No	24	60.00
Yes	16	40.00
Total	40	100.00

**Table 13:** Show the percentage of bone marrow contusion in the study.

<b>Bone Marrow contusion</b>		
	<b>N</b>	<b>%</b>
No	28	70.00
Yes	12	30.00
Total	40	100.00

**Table 14**

<b>Bone Marrow contusion</b>		
	<b>N</b>	<b>%</b>
Traumatic	10	83.33
Non Traumatic	2	16.67
Total	12	100.00

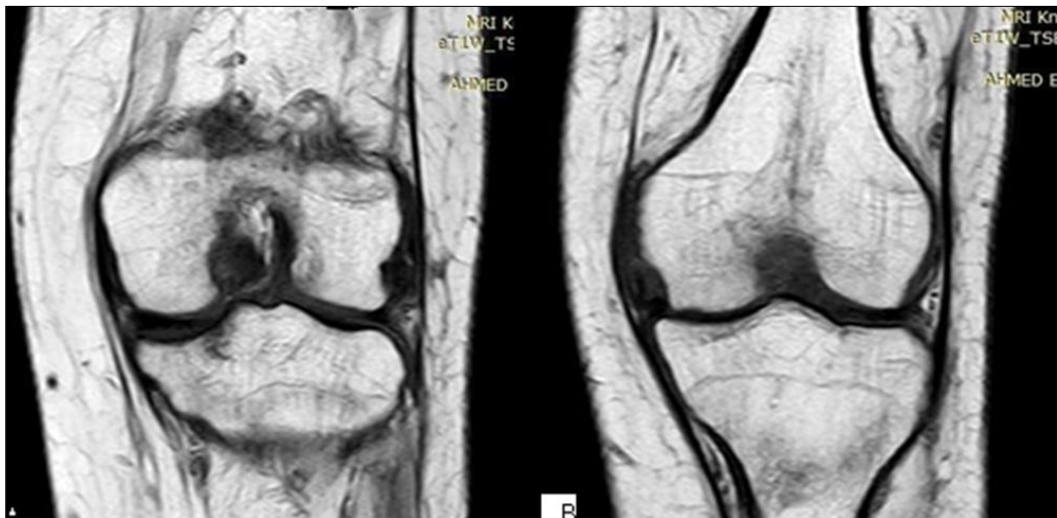
**Table 15:** Show the percentage of joint effusion associated other injuries.

<b>joint effusion with other injuries</b>		
	<b>N</b>	<b>%</b>
Med. Meniscus	18	75.00
Lat. Meniscus	12	50.00
Anterior cruciate ligament	10	41.67
posterior cruciate ligament	4	16.67
Lateral Collateral Ligament	4	16.67
Medial Collateral Ligament	4	16.67

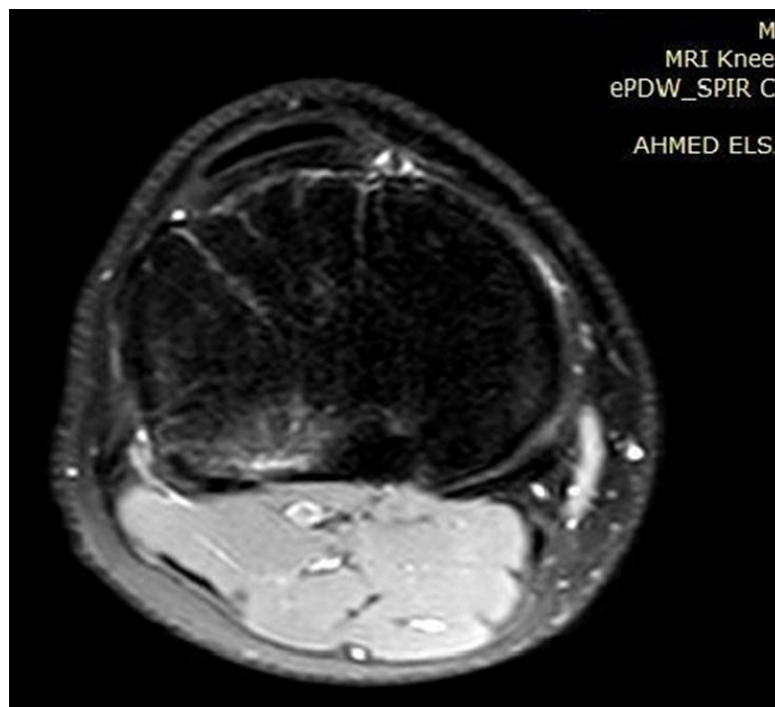
Osteoarthritis change	10	41.67
Bone Marrow contusion	8	33.33

**Table 16:** Finally the table below will demonstrate the overall injuries percentage in our study.

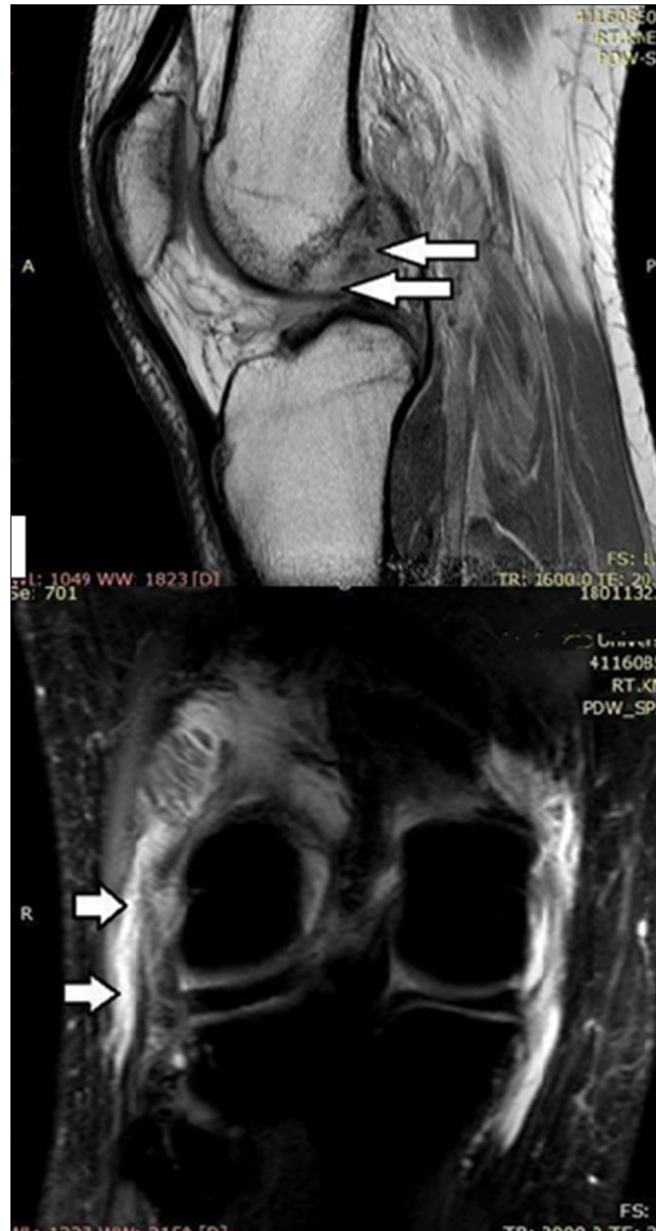	N	%
Meniscus	28	70.00
Anterior cruciate ligament	18	45.00
posterior cruciate ligament	4	10.00
Lateral Collateral Ligament	6	15.00
Medial Collateral Ligament	10	25.00
Osteoarthritis change	16	40.00
Tendon	4	10.00
Bone Marrow contusion	12	30.00
Synovial thickening	4	10.00
joint effusion	24	60.00



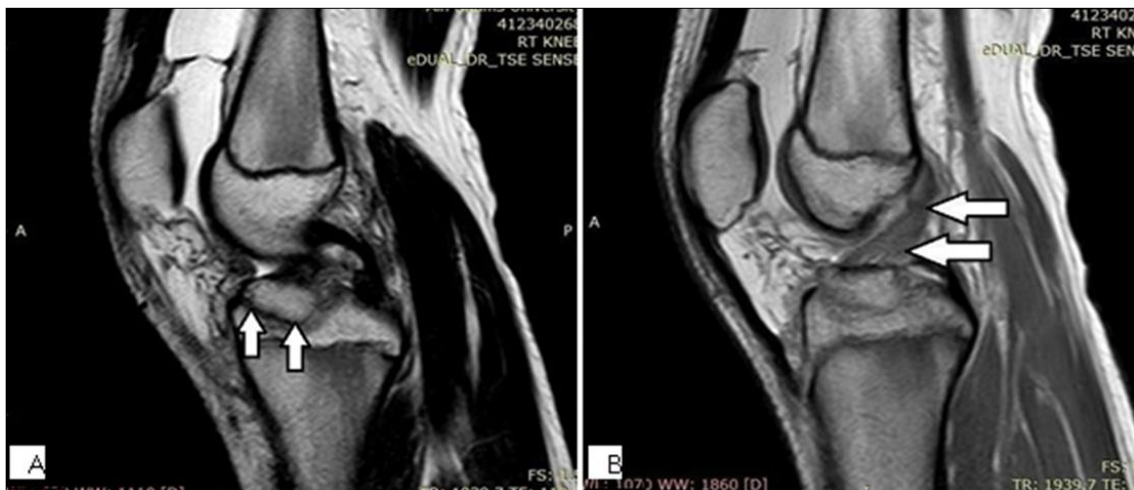**Fig 1:** A: Coronal T1W knee MR image demonstrating Medial Collateral Ligament sprain. The Medial Collateral Ligament is seen encased by fluid signal denoting its sprain. B: Coronal T1W knee MR image demonstrating anterior cruciate ligament partial tear. We see fluid collection within and around it



**Fig 2:** knee MRI image demonstrating high signal on fat suppression sequence diagnosed as marrow contusion in posterior tibial condyle.



**Fig 3:** (A): Sagittal PDW knee MR image demonstrating complete tear of Anterior cruciate ligament fibers with no surrounding soft tissue edema suggesting chronic tear (arrows). (B): Sagittal PDW (SPAIR) knee MR image, lateral Collateral Ligament shows faint bright signal suggesting its sprain (arrows).



**Fig (A):** Sagittal T2W knee MR image, fracture line at the tibial plateau with minimal displacement of the fractured segment (arrows). (B): Sagittal PDW knee MR image, the anterior cruciate ligament is thickened and hyperintense denoting edema and sprain (arrows).

## Discussion

During the period from November 2020 to October 2021, 40 patients were examined by MRI, they were 28 males and 12 females. They presented with knee pain due to various knee joint problems.

Regarding sex distribution; (70%) were males while (30%) were females and this agreed with Yadav and Kachewar (2013) [27] that show the distribution of gender were (66%) male and (34%) female, agreed with Mehta et al. (2015) [17] that show (72%) male and (28%) female, and also agreed with Gupta et al. (2012) [7] that show (86.66%) male while (13.33%) female, in all above studies were male more than female. This could be because of more activities in males during sports as compared to females and they are also more prone to accidents.

The mean age in our study was  $38.55 \pm 13.37$  years, that agreed with Yadav and Kachewar (2014) was  $36.70 \pm 13.14$ . The analysis of injuries distribution in our study showed that the commonest one was the meniscal injury (70%). The nearest result have been shown by Nasir (2013) [19] in which meniscal injury appearance was (52%), but disagreed with that shown by Majewski et al. (2006) [15] which is a 10 years study of 6434 athletic knee injuries as it demonstrated meniscus lesion (14.5%).

Our study demonstrated that the best pulse sequence for evaluation of menisci was PD fat suppressed and this was similar to results of Stoller et al. (2007) [11] study. Helms (2002) [8] postulated that with fat suppression, the dynamic range signal of the menisci is increased, making meniscal tears more conspicuous. In this study Helms (2002) [8] STIR sequences were used in all patients.

Meniscus tears were more conspicuous on STIR sequences favouring Helms postulation. Rubin and Paletta (2000) [22] have stated that virtually all meniscus tears are detected and characterised on sagittal plane imaging only. Magee and Williams (2006) [3] concluded that coronal MR images of the knee allowed better detection and characterisation of some meniscal tears than sagittal images alone. However, in our study we found that both sagittal and coronal images were necessary in accurately diagnosing meniscal injuries.

In case of anterior cruciate ligament tears, they diagnosed in (45%) of cases and this finding was similar to that of Nasir (2013) [19] in which the appearance of anterior cruciate ligament injuries was (32%) but not in accordance with Swenson et al., (2013) [26] study which showed that anterior cruciate ligament forms only (25.4%) of knee injuries.

According to planes and pulse sequences, we found that a sagittal PD FSE sequence was the best one for appreciation of the anterior cruciate ligament. Oei et al., (2007) [20] study showed that the anterior cruciate ligament usually evaluated on T2- weighted or proton density-weighted images in the sagittal plane, but images in the axial and coronal plane can be helpful in assessing the femoral and tibial attachments. Although the cruciate ligaments are best seen on sagittal images, they can also be identified on coronal images (Khanna et al., 2001) [10].

posterior cruciate ligament injury represented (10%), a result agreed with Pasupuleti et al., (2015) [21] that shown (10%). also agreed with Hetta and Niazi (2014) [9] in which PCL injuries founded in (8%) The posterior cruciate ligament is best evaluated on the T2-weighted sagittal images and is typically visualized in its entirety on a single image or more commonly on 2 consecutive sagittal images. Axial and coronal planes are complementary but rarely necessary in the evaluation of the posterior cruciate ligament (De Abreu et al., 2005).

Regarding collateral ligaments injury, it represented (35%) of cases and this agreed with Hetta and Niazi (2014) [9] that shown (32%) but disagreed with Majewski et al. (2006) [15] who demonstrated that the collateral ligaments form only (9%) of knee injuries.

MCL injury represented (25%), a result agreed with Swenson et al., (2013) [26] that shown (35%) and agreed with Nasir (2013) [19] in which MCL injuries founded in (18%). LCL injuries appeared in (15%), that agreed with Pasupuleti et al., (2015) [21] which show (16%), also agreed with Swenson et al., (2013) [26] that founded in (9%).

Khanna et al., (2001) [10] stated that collateral ligaments are best seen on coronal T1 and T2- weighted images. Increased signal intensity on T2-weighted images is compatible with edema and indicates the acuity of the injury. T1-weighted images can be used to follow the contour of the ligaments and to differentiate a ligamentous sprain from a complete (grade-III) tear.

A coronal T2-weighted sequence is necessary to demonstrate collateral ligament lesions as demonstrated by Oei et al. (2007) [20] and De Maeseneer et al. (2000). We found that collateral ligaments were best seen by coronal PD fat suppressed sequence. Muscular injury formed (10%) and this was in accordance with Hetta and Niazi (2014) [9] study that show (8%), and also agreed with Mehta et al., (14%) but disagreed with Swenson et al. (2013) [26] who showed that (29.5%) of cases were muscular injuries. The extensor mechanism structures are best assessed on sagittal MR images. The patellar retinaculum is an important stabiliser of the patellofemoral joint, and is best evaluated on axial MR images (Lim and Peh, 2008) [12] and we found that the extensor mechanism tendons were best seen by sagittal PD FSE sequence and the patellar retinaculum by axial T2WI. Bone injuries formed about (30%) of knee pain in our study and this was in agreement with a study of Hetta and Niazi (2014) [9] in which (20%), but disagreed with that of Mehta et al., (2015) [17] which demonstrated that the bone injury form (62%).

Masala et al. (2003) study demonstrated that the bone marrow abnormalities are best evaluated with fat-suppression techniques such as short time inversion recovery (STIR) or selective partial inversion recovery (SPIR), and these imaging protocols should be used in all cases of suspected stress-related injury. Joint effusion appear in about (60%) of cases in our study and this was in agreement with a study of Mehta et al., (2015) [17] in which (74%), but disagreed with that of Nasir (2015) which demonstrated that joint effusion form (20%)

## Conclusion

MR imaging is the best imaging modality for diagnosis of different knee lesions and can be considered as replacing of other invasive modalities for diagnosis of different knee lesions and the best plane and pulse sequence for each injury was as following: Sagittal PD FSE sequence for appreciation of the anterior cruciate ligament, posterior cruciate ligament and the extensor mechanism tendons, Coronal & Sagittal PD fat suppressed

sequence for menisci., PD fat suppressed sequence for menisci, collateral ligaments and articular cartilage and T2W images help in demonstration of joint effusion

### Recommendations

MRI has a role in meniscal and cruciate ligament lesions, when the indication for arthroscopy is less clear-cut but more studies are needed in this field.

### Reference

1. Arumugam V, Ganesan G, Natarajan P. MRI evaluation of Acute Internal Derangement of Knee. Open Journal of Radiology,2015;5:66-71.
2. Berquist TH. Osseous and Myotendinous Injuries about the Knee. Radiol Clin N Am 2007;45:955-968.
3. Berquist TH, Kelley EA. The knee. In: Berquist TH, editor. MRI of the musculoskeletal system. 5th edition. Philadelphia: Lippincott- Williams and Wilkins,2006, 303-429.
4. Dugan SA. Sports-related knee injuries in female athletes: what gives? Am Phys Med Rehabil,2005;84:122-130.
5. Englund M, Felson DT, Guermazi A, Roemer FW, Wang K, Crema MD, *et al.*: Risk factors for medial meniscal pathology on knee MRI in older US adults: a multicentre prospective cohort study. Ann Rheum Dis,2011;70:1733-1739.
6. Fox MG. MR Imaging of the Meniscus: Review, Current Trends, and Clinical Implications. Radiol Clin N Am,2007;45:1033-1053.
7. Gupta S, Sharma R, Sachar A, Saini A, Saini N. Comparison Of Clinical Examination, MRI And Arthroscopy In Knee Injuries. The Internet Journal of Orthopedic Surgery,2012;3:1-6.
8. Helms CA. The meniscus: recent advances in MR imaging of the knee. AJR,2002;179(5):1115-1122.
9. Hetta W, Niazi G. MRI in assessment of sports related knee injuries. The Egyptian Journal of Radiology and Nuclear Medicine,2014;45:1152-1165.
10. Khanna AJ, Cosgarea AJ, Mont MA. Magnetic Resonance Imaging of the Knee: Current Techniques and Spectrum of Disease. J Bone Joint Surg Am,2001;83(2):S128-141.
11. Lejay H, Holland BA. Technical advances in musculoskeletal imaging In Stoller D.W. (eds): Magnetic resonance imaging in orthopaedics and sports medicine. Lippincott Williams & Wilkins, third Edition,2007:P1-28.
12. Lim SY, Peh WC. Magnetic Resonance Imaging of Sports Injuries of the Knee. Annals Academy of Medicine,2008;37:4.
13. Litwic A, Edwards MH, Dennison EM, Cooper C. Epidemiology and burden of osteoarthritis. Br Med Bull. 2013;105:185-199.
14. Magee T, Williams D. 3.0-T MRI of Meniscal Tears. AJR Am J Roentgenol,2006;187:371-375.
15. Majewski M, Susanne H, Klaus S. Epidemiology of athletic knee injuries: a 10-year study. Knee,2006;13(3):184-188.
16. Masala S, Fiori R, Marinetti A., *et al.*: Imaging the ankle and foot and using magnetic resonance imaging. Int J Low Extrem Wounds,2003;2:217-232.
17. Mehta R, Aghari NS, Agarwal S, Bhargava A. MRI detected prevalence of abnormalities in patients of knee pain. International Journal of Research in Medical Sciences, 2015;3(10):2572-2575.
18. Miyamoto RG, Bosco JA, Sherman OH. Treatment of medial collateral ligament injuries. J Am Acad Orthop Surg,2009;17:152-61.
19. Nasir A. The role of magnetic resonance imaging in the knee joint injuries, international research journal of medical science,2013;1(5):1-7.
20. Oei EHG, Ginai AZ, Hunink MGM. Seminars in Ultrasound, CT and MRI,2007;28:141-157.
21. Pasupuleti B, Kosti SK, Narra R, Jukuri N. MRI Evaluation of Painful Knee: A Study at Katuri Tertiary Referral Center. Journal of Evidence based Medicine and Healthcare,2015;2(7):888-897.
22. Rubin DA, Paletta GA. Current concepts and controversies in meniscal imaging. Magn Reson Imaging Clin N Am,2000;8:243-270
23. Ryan S, McNicholas M, Eustace SJ. The lower limb anatomy; Anatomy for Diagnostic Imaging; 3rd edition ELSEVIER Saunders Ltd, Philadelphia (US),2011;8:253-274.
24. Snell RS. Clinical anatomy by systems, 1st edition. Philadelphia, PA: Lippincott Williams & Wilkins, 2007.
25. Standring S. Gray's anatomy: the anatomical basis of clinical practice, knee. 40th ed. ELSEVIER Churchill Livingstone, London,2008:1393-1409.
26. Swenson DM, Collins CL, Best TM. Epidemiology of knee injuries among US high school athletes. Med Sci Sports Exerc,2013;45(3):462-469.
27. Yadav R, Kachewar SG. Role of MRI in evaluation of painful knee. Int J Med Res Health Sci,2013;3(1):84-7.