



---

## Clinical images manifestation of duhring's disease: A review article

Nanda Rachmad Putra Gofur<sup>1\*</sup>, Aisyah Rachmadani Putri Gofur<sup>2</sup>, Soesilaningtyas<sup>3</sup>, Rizki Nur Rachman Putra Gofur<sup>4</sup>, Mega Kahdina<sup>4</sup>, Hernalia Martadila Putri<sup>4</sup>

<sup>1</sup> Department of Health, Faculty of Vocational Studies, Universitas Airlangga, Surabaya, East Java, Indonesia

<sup>2</sup> Faculty of Dental Medicine, Universitas Airlangga, Surabaya, East Java, Indonesia

<sup>3</sup> Department of Dental Nursing, University Poltekkes Kemenkes, Surabaya, East Java, Indonesia

<sup>4</sup> Faculty of Medicine, Universitas Airlangga, Surabaya, East Java, Indonesia

---

### Abstract

**Introduction:** Duhring disease is a autoimmune disease. The clinical manifestation may vary. Rash is polymorphic, mainly in the form of vesicles that are arranged in groups and symmetrical. Symptoms vary in intensity but many sufferers complain of a very severe itching, burning and burning sensation with predilection, especially on the extensor surface of the upper and lower limbs, elbows, knees, scalp, back of the neck (nape), back, shoulders, sacrum area and butt. The face and groin can also be affected.

**Discussion:** Due to intense itching associated with the disease, patients often scratch the vesicles and this results in an appearance that appears only to be erosion and excoriation. Symptoms vary in intensity but many sufferers complain of intense itching, burning and intense burning. Which is often without precedence overt mainstream lesions within hours. Lesions that appear on the head, face, thighs and flexor area are seen in more severe cases. Pustules are very rare except when secondary infection occurs. Vesicles that arise especially if they are on the hands may be hemorrhagic. Lesions that appear and disappear continuously, will cause hypopigmentation and hyperpigmentation.

**Conclusion:** The main lesions of dermatitis herpetiformis are clusters of erythematous papules, urticarial plaques or most commonly vesicles that appear in groups but may also appear in groups. Papu lovesicles 'herpetiformis' 3–6 mm in size with an erythematous base are characteristic of the disease, large bullae are rare.

**Keywords:** duhring's disease, vesibolous, herpetiformis, autoimmune

---

### Introduction

Dermatitis herpetiformis or also known as duhring disease is a rare autoimmune vesicobulosa disease, specific and recurrent chronic in nature and has a relationship with celiac disease and gluten-sensitive enteropathy. The rash is polymorphic, mainly in the form of vesicles that are arranged in groups and symmetrical. Symptoms vary in intensity but many sufferers complain of a very severe itching, burning and burning sensation with predilection, especially on the extensor surface of the upper and lower limbs, elbows, knees, scalp, back of the neck (nape), back, shoulders, sacrum area and butt. The face and groin can also be affected. Dermatitis Herpetiformis can affect any age, but appears more often for the first time in young adults between the ages of 30 and 40, more often in men than in women <sup>[1, 2]</sup>

Dermatitis herpetiformis (DH) is a chronic condition that has problems with severe itching, skin rashes, and blisters that are a manifestation of enteropathy, due to intolerance to gluten (gluten-sensitive enteropathy) or commonly referred to as celiac disease, DH or what is also known. Known as Dühring's disease, affects or occurs in approximately 10% of patients with celiac disease. The term herpetiformis in DH tax appears on her skin blisters or lumps that appear in groups, the address of the blisters in herpes, but these blisters are not caused by herpes viruses <sup>[3, 4]</sup>.

The initial symptom that a patient with DH may notice or feel is skin that feels like burning or stinging in several locations. Then,

after these symptoms appear, small lumps appear that cluster and feel very itchy. These bumps can have distinct lines, such as: blisters, a wound that has fluid in it, deep wounds of urticaria, the wound is rising, red, thickened plaques are skin symptoms in dermatitis, scabies and papular urticaria, erosion or crusting due to scratching of itchy skin <sup>[5, 6]</sup>.

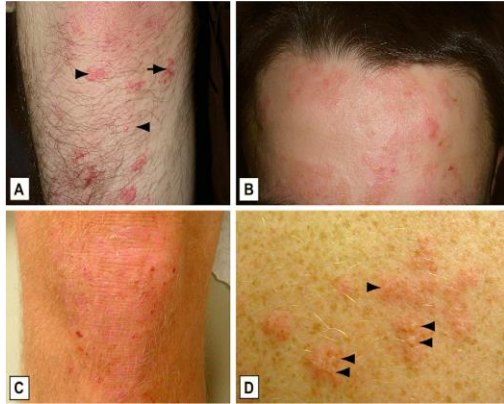
At this stage, the clinical skin manifestations of DH are often mistaken for eczema. Often, the clinical skin manifestations of DH appear in certain areas. It is possible that these skin manifestations also appear on the body, neck, around the thighs, and even appear on tooth enamel. Generally, these skin manifestations appear on both sides of the body or have a symmetrical distribution. The blisters on DH generally dry up and heal within 1-2 weeks. However, new blisters appear at the same location, so that the blisters on DH appear as chronic blisters that don't go away. In the manifestations of healed DH skin, post-inflammatory hypopigmentation or hyperpigmentation may appear <sup>[7, 8]</sup>.

### Discussion

#### Clinical Manifestation of Duhring's Disease

The main lesions of dermatitis herpetiformis are clusters of erythematous papules, urticarial plaques or most commonly vesicles that appear in groups but may also appear in groups.

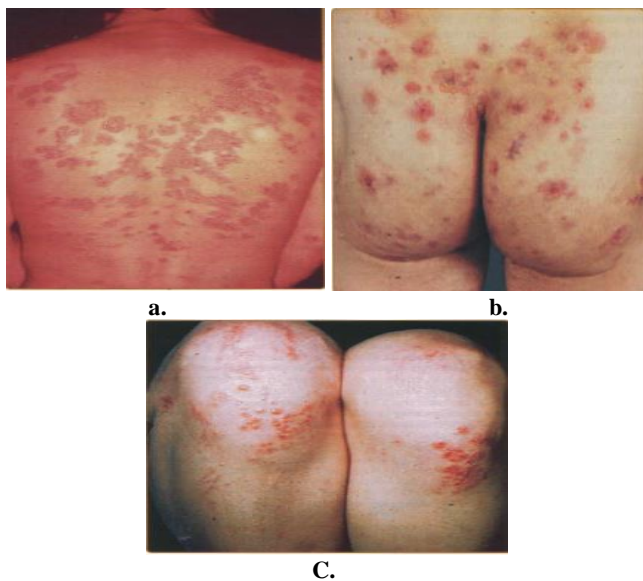
Papulovesicles 'herpetiformis' 3–6 mm in size with an erythematous base are characteristic of the disease, large bullae are rare [1, 4]. Due to intense itching associated with the disease, patients often scratch the vesicles and this results in an appearance that appears only to be erosion and excoriation. Examples of primary and secondary efflorescence in patients with dermatitis herpetiformis can be seen in Figures below [1, 4, 8, 9].



**Fig 1:** Dermatitis herpetiformis's clinical manifestation

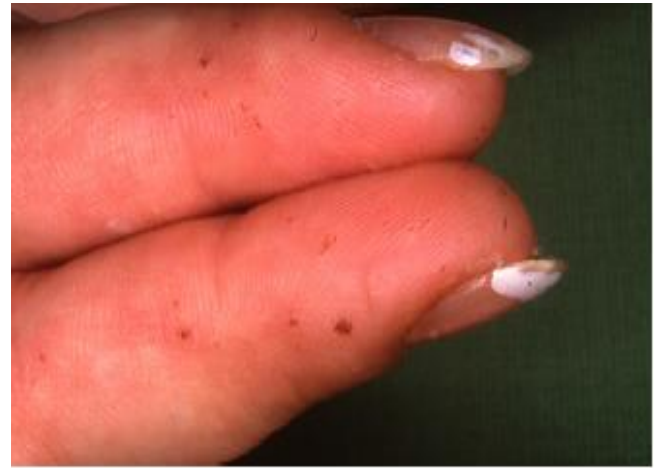A. Plaque and papules on the elbow, excoriation and vesicles. B. Edema, plaques, and papules on the forehead and scalp. C Excoriation and hemorrhagic crust on the knee. D. Cescicles on reddish back [9].

Symptoms vary in intensity but many sufferers complain of intense itching, burning and intense burning. Which is often without precedence overt mainstream lesions within hours. Lesions that appear on the head, face, thighs and flexor area are seen in more severe cases. Pustules are very rare except when secondary infection occurs. Vesicles that arise especially if they are on the hands may be hemorrhagic. Lesions that appear and disappear continuously, will cause hypopigmentation and hyperpigmentation [1, 3, 8].



**Fig 2:** Wide eruption with papules, vesicles, and crusta on the back (A) Vesicles and bullae with clear margin, some erosion and hyperpigmentation, vesicles are in annular pattern (B). Papules, vesicles, and crustae on the knee (C) [1, 4]

A rare clinical manifestation is purpura on the palms. This clinical picture is more common in children, but several cases in adults have also been reported. Clinically purpura appears on the hands, as in Figure 3, and / or the soles of the feet. It is suspected that trauma is an etiological factor. No dorsal surface involvement of the hands and feet was reported [1, 4].



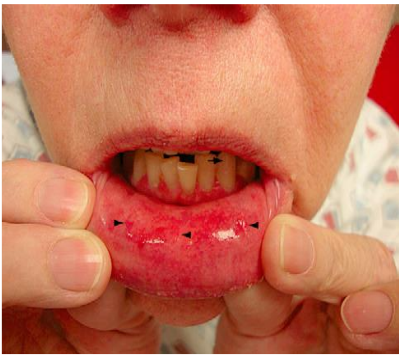**Fig 3:** Purpura on the fingers of patient suffering from dermatitis herpetiformis [4]

Mucosal involvement is very rare in dermatitis herpetiformis. Many studies reported a lack of information on oral lesions by direct immunofluorescence examination of the oral mucosa. Dermatitis herpetiformis is associated with various conditions, such as celiac disease and autoimmune connective tissue disease which may cause lesions in the mouth itself, thus there are many possible causes of mucosal lesions in dermatitis herpetiformis patients [1, 8].

Although limited, several studies suggest that oral mucosal lesions are associated with the diagnosis of dermatitis herpetiformis, where there are vesicles, erythematous macules and erosions of the oral mucosa as shown in Figure 4, including the tongue. This condition causes painful swallowing and a burning sensation [8].

It is important to note, however, that celiac disease itself is associated with apoptosis of the mouth and mucosal lesions. Therefore, the relationship between oral mucosal lesions in dermatitis herpetiformis remains unclear. Finally, dental abnormalities have been explained in patients with celiac disease and patients with dermatitis herpetiformis. Defects in enamel on permanent teeth, as in Figure 4, are seen in children and adults with celiac disease and dermatitis herpetiformis. Horizontal grooves, defects in tooth enamel color and large holes in the enamel are characteristic features of teeth in patients with dermatitis herpetiformis [1, 8].

Although not found in all patients with dermatitis herpetiformis, they are associated with gastrointestinal abnormalities caused by gluten sensitivity. From the study, patients with dermatitis herpetiformis also found symptoms of steatorrhea (20-30% of patients) [2].

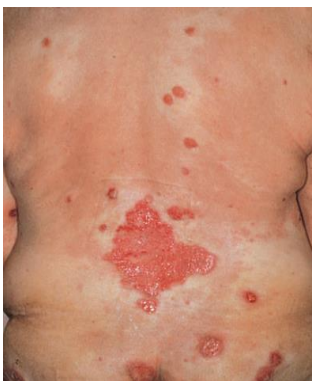

**Fig 4:** Multiple erosion on the lips <sup>[8]</sup>

### Differential Diagnosis

Dermatitis herpetiformis has several similarities with the following diseases, so that these diseases are often used as a differential diagnosis rather than dermatitis herpetiformis, they are pemphigoid vulgaris, pemphigoid bullosa, and linear IgA dermatosis. In pemphigoid vulgaris, the main cause of this disease is autoimmune. The prevalence of patients who most often appear is between the 3-6 decades (30-60 years). The main complaint of patients is usually not itching. And on physical examination found loose-walled bullae and if there is a rupture, crusts can arise which persist for a long time <sup>[1]</sup>.

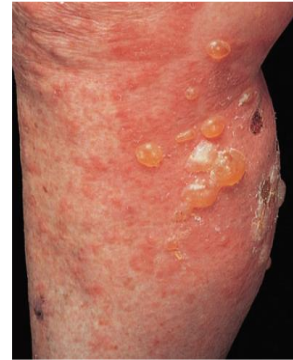The clinical picture is shown in Figure 5. In 60% pemphigus vulgaris, there are abnormalities in the oral mucosa. Nikolsky's sign for pemphigus vulgaris is positive. This disease predilection is general (can appear in all parts of the body). If a direct immunofluorescence examination is performed, IgG and its complement can be seen in the epidermis. This disorder does not involve gastrointestinal disorders, disorders related to gluten sensitivity, and no involvement of HLA. Therapy of this disease is carried out using corticosteroids and cytostatics. <sup>[1, 7, 10]</sup>



**Fig 5:** Patient with pemphigus vulgaris on sacrum area. It is shown krusta <sup>[10]</sup>

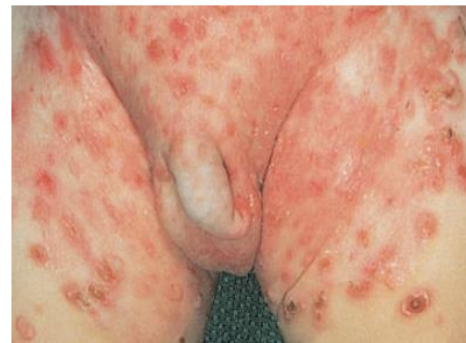In pemphigoid bullosa, the main cause of the disease is suspected to be autoimmune. The prevalence of sufferers is in old age (over 60 years). The main complaint of patients is usually not itching. And on physical examination, a tense walled bullae was found as shown in Figure 15. In 10-40% of pemphigoid bullosa, there are abnormalities in the oral mucosa. The Nikolsky sign on pemphigoid bullosa is negative. The predilection for this disease is the abdomen, flexor arms, groin and medial legs. If a direct immunofluorescence examination is performed, it can be seen that IgG is shaped like a band on the basal membrane. This

disorder does not involve gastrointestinal disorders, disorders related to gluten sensitivity, and no involvement of HLA. Therapy of this disease is carried out using corticosteroids <sup>[7, 11]</sup>.



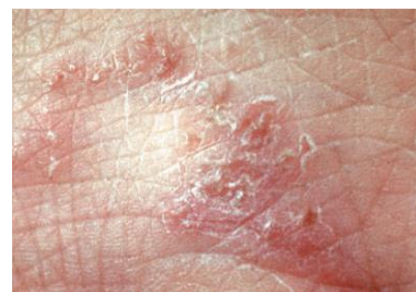**Fig 6:** Patients with pemphigoid bullosa <sup>[11]</sup>

For Linear IgA dermatosis as shown in Figure 6, differentiation from dermatitis herpetiformis will be difficult if it only relies on clinical and histopathological examinations. Additional examination in the form of immunological examination will be able to distinguish these two diseases <sup>[7, 12]</sup>.



**Fig 7:** Linear IgA dermatosis in children has a clinical picture similar to dermatitis herpetiformis so it is difficult to distinguish it. The diagnosis is confirmed by performing an immunological examination <sup>[12]</sup>.

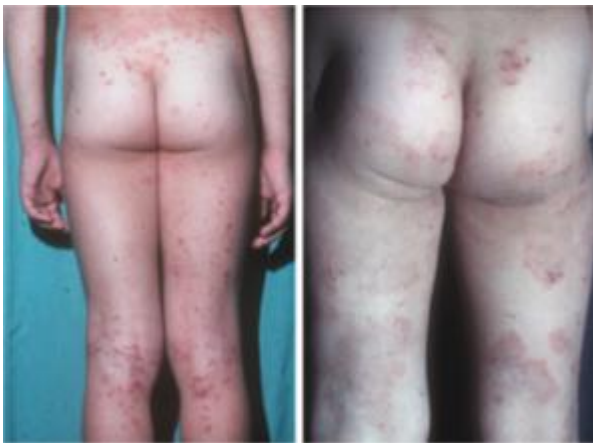Authors in other literature have also found that dermatitis herpetiformis was diagnosed as compared to scabies, and hypersensitivity was due to insect bites. For scabies, the morphology of the scabies is papules, vesicles and a scabies tunnel as a pathognomonic sign as shown in Figure 7. The distribution of scabies is usually in the gaps of the fingers, wrists, ulnar region of the forearm, genitals and lower abdomen. It stands out is that scabies definitely responds to anti-scabies therapy <sup>[7]</sup>



**Fig 8:** Clinical sign of scabies <sup>[13]</sup>.

In the field of pediatric dermatology as shown in Figure 8, it is not uncommon for dermatitis herpetiformis to be diagnosed differently with atopic dermatitis. This is because when there are complaints of intense itching on the skin of the child, which is accompanied by chronic inflammatory lesions it is usually due to atopic dermatitis, and rarely due to dermatitis herpetiformis, which is the most classic manifestation of celiac disease. The difference between the two is that the history of atopic dermatitis refers to a family and / or personal history of atopy. The prevalence of atopic dermatitis was 12.8% of all childhood diseases, while DH was 0.1% of all diseases in children. Atopic dermatitis the prevalence can be at any age, but 50% more occurs in the first 6 months of life<sup>[13]</sup>.

Whereas in dermatitis herpetiformis, the infantile form begins to appear in the second year of life. The lesion type atopic dermatitis is eczematous, whereas in dermatitis herpetiformis the lesions are typically erythematous and infiltrative lesions with flat, circinate surfaces with easily visible vesicles. The distribution of lesions in atopic dermatitis in children in the first year of life is often on the face, and in the following, on the flexor surfaces of the elbows and knees. Whereas in children suffering from dermatitis herpetiformis, the lesions are usually centripetal, often on the chest, especially the scapular region and the base of the trunk, especially the triangular area of the extensor surface of the forearm with a base on the elbow. In atopic dermatitis, the skin prick test for atopy is often positive, and in atopic dermatitis there is no improvement in the introduction of a gluten-free diet<sup>[1,7,14]</sup>.



**Fig 9:** Comparison of atopic dermatitis and dermatitis herpetiformis (Left) Pediatric patients suffering from atopic dermatitis, (Right) pediatric patients suffering from dermatitis herpetiformis<sup>[14]</sup>

## References

- Ronaghy A, Katz SI, Hall RP. Dermatitis herpetiformis. In: Goldsmith LA, Katz SI, Gilchrist BA, Paller AM, Leffell DJ, Wolff K, editors. *Fitzpatrick's Dermatology in General Medicine*. 8<sup>th</sup> ed. New York: Mc Graw Hill Medical, 2012, 1199-211.
- Reunala TL. Dermatitis herpetiformis. *Clinics in Dermatology*. 2001; 19:728-36.
- Antiga E, Caproni M, Fabbri P. Dermatitis herpetiformis: novel advances and hypotheses. *World J Dermatol*. 2012; 1:24-9.
- Karpati S. Dermatitis herpetiformis. *Clinics in Dermatology*. 2012; 30:56-9.
- Prasant J. A review on dermatitis herpetiformis. *International Journal of Pharma and Review*. 2014; 3:72-8.
- Bonciani D, Verdelli A, Bonciolini V, D'Errico A, Antiga E, Fabbri P, *et al*. Review article: dermatitis herpetiformis: from the genetics to the development of skin lesions. *Clinical and Developmental Immunology*, 2012. Article ID 239691.
- Caproni M, Antiga E, Melani L. Review article: guidelines for the diagnosis and treatment of dermatitis herpetiformis. *Journal European Academy of Dermatology and Venereology*. 2009; 23:633-8.
- Bolotin D, Rosic VP. Dermatitis herpetiformis: Part I Epidemiology, pathogenesis, and clinical presentation. *J Am Acad Dermatol*. 2011; 64:1017-24.
- Anwar MI, Rashid A, Tahir M, Ijaz A. Review article: Guidelines for the management of dermatitis herpetiformis. *Journal of Pakistan Association of Dermatologists*. 2013; 23:428-35.
- Payne AS, Stanley JR. Pemphigus. In: Goldsmith LA, Katz SI, Gilchrist BA, Paller AM, Leffell DJ, Wolff K, editors. *Fitzpatrick's Dermatology in General Medicine*. 8<sup>th</sup> ed. New York: Mc Graw Hill Medical. 2012, 1100-22.
- Culton DA, Liu Z, Diaz LA. Bullous pemphigoid. In: Goldsmith LA, Katz SI, Gilchrist BA, Paller AM, Leffell DJ, Wolff K, editors. *Fitzpatrick's Dermatology in General Medicine*. 8<sup>th</sup> ed. New York: Mc Graw Hill Medical, 2012, 1136-49.
- Rao CL, Hall RP. Linear immunoglobulin a dermatosis and chronic bullous disease of childhood. In: Goldsmith LA, Katz SI, Gilchrist BA, Paller AM, Leffell DJ, Wolff K, editors. *Fitzpatrick's Dermatology in General Medicine*. 8<sup>th</sup> ed. New York: Mc Graw Hill Medical, 2012, 1162-75.
- Bukhart CN, Burkhardt CG. Scabies. In: Goldsmith LA, Katz SI, Gilchrist BA, Paller AM, Leffell DJ, Wolff K, editors. *Fitzpatrick's Dermatology in General Medicine*. 8<sup>th</sup> ed. New York: Mc Graw Hill Medical, 2012, 4822-9.
- Bonifazi E, *Differential Diagnosis in Pediatric Dermatology*. Italia: Springer-Verlag, 2013, 78-9.